

Tracheostomy Tube Emergencies

History

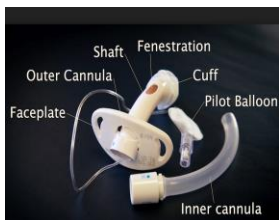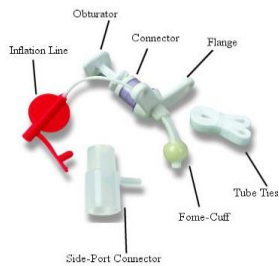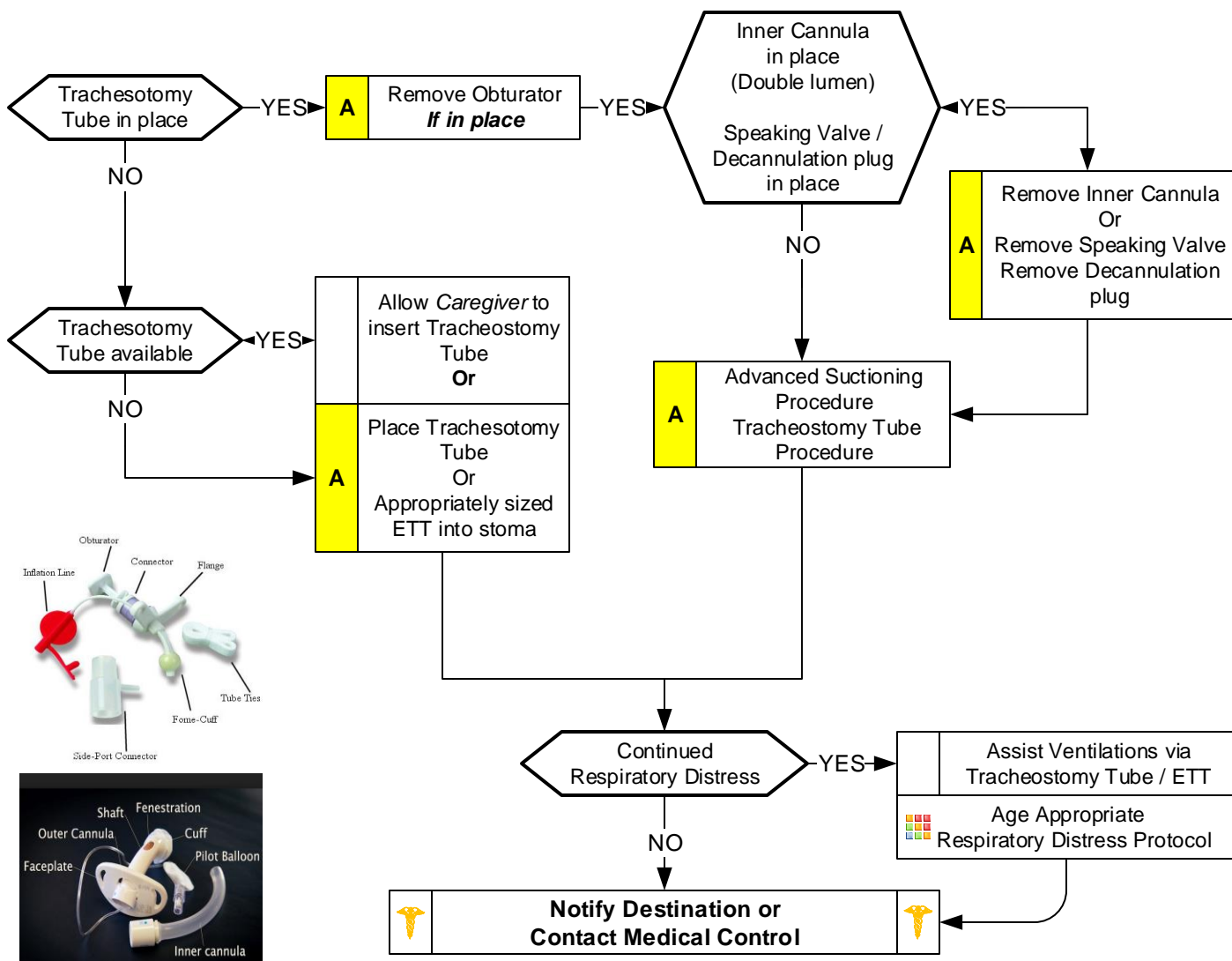
- Birth defect (tracheal atresia, tracheomalacia, craniofacial abnormalities)
- Surgical complications (accidental damage to phrenic nerve)
- Trauma (post-traumatic brain or spinal cord injury)
- Medical condition (bronchial or pulmonary dysplasia, muscular dystrophy)

Signs and Symptoms

- Nasal flaring
- Chest wall retractions (with or without abnormal breath sounds)
- Attempts to cough
- Copious secretions noted coming out of the tube
- Faint breath sounds on both sides of chest despite significant respiratory effort
- AMS
- Cyanosis

Differential

- Allergic reaction
- Asthma
- Aspiration
- Septicemia
- Foreign body
- Infection
- Congenital heart disease
- Medication or toxin
- Trauma



Pearls

- Always talk to family / caregivers as they have specific knowledge and skills.
- Important to ask if patient has undergone laryngectomy. This does not allow mouth/nasal ventilation by covering stoma.
- Use patients equipment if available and functioning properly.
- Estimate suction catheter size by doubling the inner tracheostomy tube diameter and rounding down.
- Suction depth: Ask family / caregiver. No more than 3 to 6 cm typically. Instill 2 – 3 mL of NS before suctioning.
- Do not suction more than 10 seconds each attempt and pre-oxygenate before and between attempts.
- DO NOT force suction catheter. If unable to pass, then tracheostomy tube should be changed.
- Always deflate tracheal tube cuff before removal. Continual pulse oximetry and EtCO2 monitoring if available.
- **DOPE**: Displaced tracheostomy tube / ETT, **O**bstructed tracheostomy tube / ETT, **P**neumothorax and **E**quipment failure.