



# Pediatric Tachycardia

## Narrow Complex ( $\leq 0.09$ sec)

### History

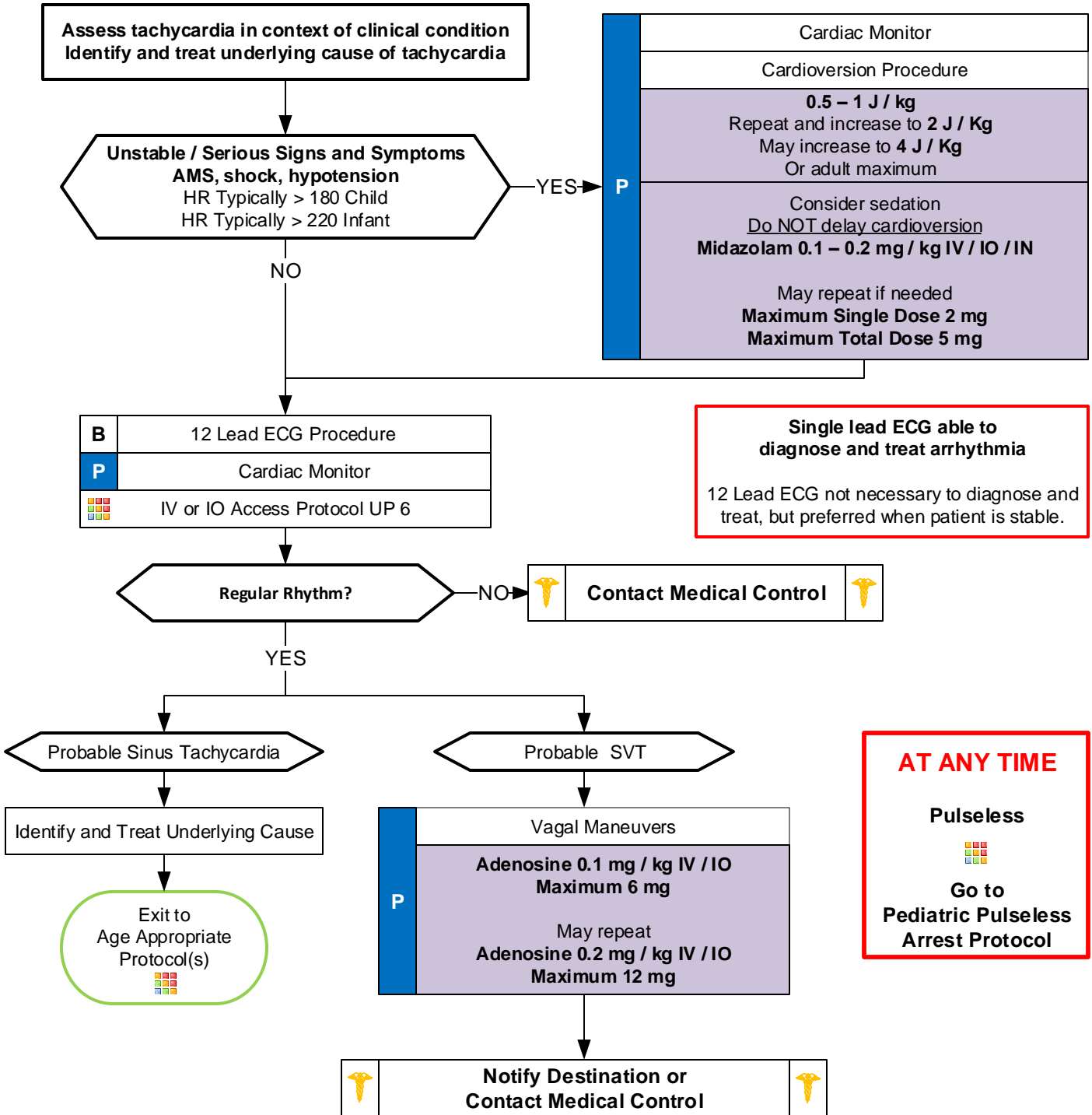
- Past medical history
- Medications or Toxic Ingestion (Aminophylline, Diet pills, Thyroid supplements, Decongestants, Digoxin)
- Drugs (nicotine, cocaine)
- Congenital Heart Disease
- Respiratory Distress
- Syncope or Near Syncope

### Signs and Symptoms

- Heart Rate: Child  $> 180$ /bpm  
Infant  $> 220$ /bpm
- Pale or Cyanosis
- Diaphoresis
- Tachypnea
- Vomiting
- Hypotension
- Altered Level of Consciousness
- Pulmonary Congestion
- Syncope

### Differential

- Heart disease (Congenital)
- Hypo / Hyperthermia
- Hypovolemia or Anemia
- Electrolyte imbalance
- Anxiety / Pain / Emotional stress
- Fever / Infection / Sepsis
- Hypoxia, Hypoglycemia
- Medication / Toxin / Drugs (see HX)
- Pulmonary embolus
- Trauma, Tension Pneumothorax





# Pediatric Tachycardia

## Narrow Complex ( $\leq 0.09$ sec)

### Pearls

- **Recommended Exam: Mental Status, Skin, Neck, Lung, Heart, Abdomen, Back, Extremities, Neuro**
- **Monomorphic QRS:**  
All QRS complexes in a single lead are similar in shape.
- **Polymorphic QRS:**  
QRS complexes in a single lead will change from complex to complex.
- **Use length-based or weight-based pediatric resuscitation system for medication, equipment, cardioversion, and defibrillation guidance. Pediatric paddles should be used in children < 10 kg.**
- **Rhythm should be interpreted in the context of symptoms and pharmacological or electrical treatment given only when symptomatic, otherwise monitor and reassess.**
- **12-Lead ECG:**  
12-Lead ECG not necessary to diagnose and treat.  
Obtain when patient is stable and/or following rhythm conversion.  
When administering adenosine, obtaining a continuous 12-Lead can be helpful to physicians.
- **Unstable condition:**  
Condition which acutely impairs vital organ function and cardiac arrest may be imminent.  
If at any point patient becomes unstable move to unstable arm in algorithm  
If IV or IO access is in place, may administer adenosine and repeat, prior to synchronized cardioversion.
- **Document all rhythm changes with monitor strips and obtain monitor strips with each therapeutic intervention.**
- **Serious Signs and Symptoms:**  
Respiratory distress / failure.  
Signs of shock / poor perfusion with or without hypotension.  
AMS  
Sudden collapse with rapid, weak pulse
- **Narrow Complex Tachycardia ( $\leq 0.09$  seconds):**  
Sinus tachycardia: P waves present. Variable R-R waves. Infants usually < 220 beats / minute. Children usually < 180 beats / minute.  
SVT: > 90 % of children with SVT will have a narrow QRS ( $\leq 0.09$  seconds.) P waves absent or abnormal. R-R waves not variable. Usually abrupt onset. Infants usually > 220 beats / minute. Children usually > 180 beats / minute.  
Atrial Flutter / Fibrillation
- **Vagal Maneuvers:**  
Breath holding. Blowing a glove into a balloon. Have child blow out "birthday candles" or through an obstructed straw. Infants: May put a bag of ice water over the upper half of the face careful not to occlude the airway.
- **Separating the child from the caregiver may worsen the child's clinical condition.**
- **Monitor for respiratory depression and hypotension associated if Diazepam, Lorazepam, or Midazolam is used.**
- **Continuous pulse oximetry is required for all SVT Patients if available.**